

## Anaphylaxis to Etoricoxib

Couto M<sup>1</sup>, López-Salgueiro R<sup>2</sup>, Gaspar Â<sup>3</sup>

<sup>1</sup>Allergy Unit, Hospital & Instituto CUF Porto, Porto, Portugal

<sup>2</sup>Health Research Institute La Fe, Valencia, Spain

<sup>3</sup>Immunoallergy Department, CUF Descobertas Hospital, Lisbon, Portugal

J Investig Allergol Clin Immunol 2018; Vol. 28(2): 135-136  
doi: 10.18176/jiaci.0221

**Key words:** Anaphylaxis. Basophil activation test. Drug allergy. Etoricoxib.

**Palabras clave:** Anafilaxia. Test de Activación de Basófilos. Alergia medicamentosa. Etoricoxib.

Nonsteroidal anti-inflammatory drugs (NSAIDs) are one of the most frequent causes of immediate drug-induced hypersensitivity reactions worldwide. The use of selective cyclooxygenase-2 (COX-2) inhibitors as an alternative to other NSAIDs is generally considered to be safe. A meta-analysis found COX-2 inhibitors to be safe in patients with aspirin-exacerbated respiratory disease [1], and there is also evidence of their safety in patients with skin reactions, NSAID-exacerbated cutaneous disease, and NSAID-induced urticaria/angioedema [2].

Cutaneous and systemic hypersensitivity reactions may occur, especially when sulfonamide-containing coxibs are administered; however, adverse reactions to etoricoxib are very uncommon, and anaphylaxis has never been reported. A search of PubMed in March 2017 using the terms (“allergy” OR “hypersensitivity”) AND (“selective cyclooxygenase-2 inhibitors”) identified only reports of cutaneous reactions [3-7], angioedema [8], and an asthmatic reaction [9], as well as cases of anaphylaxis with celecoxib (Supplementary Material online), but none with etoricoxib.

Because of their rarity, these hypersensitivity reactions may be misdiagnosed. We present a case of anaphylaxis to etoricoxib and discuss the clinical implications.

A 49 year-old woman was referred to the allergy unit after presenting with anaphylaxis twice at the emergency department. The symptoms were sudden epigastric pain, palmoplantar pruritus, dyspnea, and generalized urticaria. The second episode started a few minutes after taking etoricoxib 90 mg. The patient was questioned about any precipitating factor related to the first episode, and she mentioned that she often took etoricoxib because of joint pain and might have taken it on the day of the reaction. She denied any food or other precipitating factor or cofactor for the second episode, and she did not remember having taken any drugs during the 3-month interval between the 2 anaphylaxis episodes. She reported previous tolerance to etoricoxib, paracetamol, diclofenac, and ibuprofen.

Her previous medical history was remarkable only for intermittent allergic rhinitis, which was controlled with antihistamines on demand.

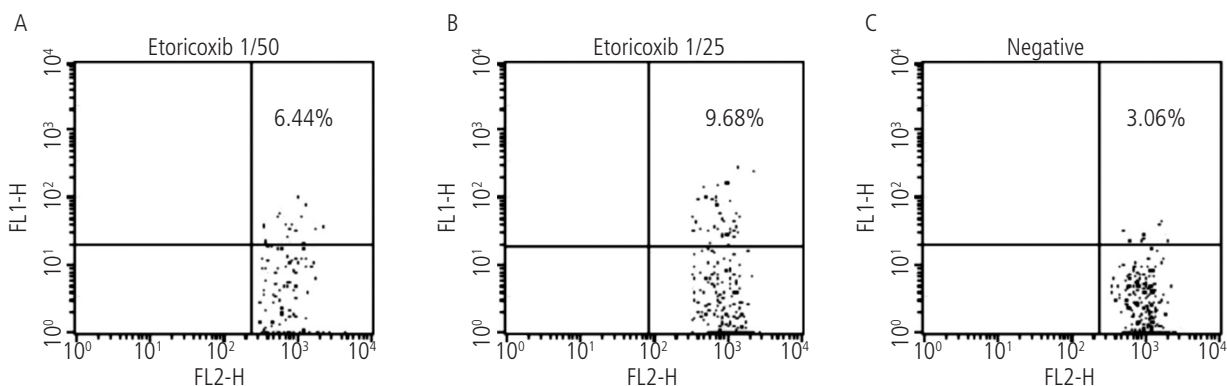
In accordance with published guidelines, a drug provocation test with the suspected NSAID is the recommended diagnostic test [2]. About 1 hour after the test (cumulative dose of 120 mg), she developed palmoplantar pruritus, oropharyngeal pruritus, lip swelling, and dyspnea; blood pressure, oxygen saturation, and pulmonary auscultation were normal. Intramuscular epinephrine 0.5 mg, oral antihistamine (hydroxyzine 25 mg), and an oral corticosteroid (prednisolone 60 mg) were administered immediately, with prompt and complete resolution of symptoms in about half an hour.

Tolerance to strong COX-1 inhibitors was subsequently confirmed at the hospital with an oral drug provocation test with acetylsalicylic acid administered gradually until a cumulative dose of 500 mg was reached, which was negative.

In order to better characterize the clinical situation, the patient consented to undergo additional testing. The allergy work-up was performed 6 months after the reaction.

Skin prick tests were performed with etoricoxib powder, as recommended in the literature [10], and included a negative control (saline) and a positive control (histamine); no reaction was observed after 15 minutes. Serum tryptase levels were within the normal range.

A basophil activation test (BAT) was performed with etoricoxib. The results are expressed as the percentage of CD63-positive basophils and the stimulation index (the ratio



**Figure.** Basophil activation test results using etoricoxib at 1/50 (A), etoricoxib at 1/25 (B), and a control (C). The stimulation index is shown for each dilution and the control.

between percentage of basophils activated after stimulation and the percentage of activated basophils in the negative control). The BAT result was positive, with >5% of basophils activated after stimulation with etoricoxib and a stimulation index >2 (Figure).

We present the first case of anaphylaxis to etoricoxib, which was confirmed by a positive oral challenge test and a positive BAT result. The usefulness of BAT in the diagnosis of hypersensitivity to etoricoxib had been demonstrated elsewhere [8]. In addition, the test highlights the role of basophils in reactions, although the complete underlying mechanism of the reaction is not clear. Given the negative skin prick test results, an IgE-mediated mechanism was not demonstrated. The structure of etoricoxib is somewhat different from that of other compounds, since one of the local phenyls is replaced by a pyridine. Etoricoxib also presents a pyridine as the central heterocyclic core. This structural difference might be the reason for the selective sensitization to etoricoxib.

Etoricoxib and celecoxib are presently the only coxibs remaining on the market (the others have been withdrawn owing to cardiovascular adverse effects). Etoricoxib is a second-generation COX-2 inhibitor. It has very high in vitro selectivity for COX-2 and is tolerated by most patients who are hypersensitive to other NSAIDs. Based on the results of previous studies, it might be tempting to prescribe this drug to multiple NSAID-hypersensitive patients without checking its tolerance in a proper setting. We hope that our findings raise awareness of potential life-threatening reactions to etoricoxib. Therefore, tolerance to NSAIDs should always be ascertained in a proper clinical setting before prescription to NSAID-hypersensitive patients.

To conclude, etoricoxib is generally tolerated by patients with hypersensitivity to NSAIDs, although this tolerance must be confirmed in a challenge test. The basophil activation test may be useful for diagnosis, as it obviates the need for an oral challenge when anaphylaxis is suspected. Further study is warranted to confirm the validity of this approach.

#### Acknowledgments

The authors would like to thank the following: Thermo-Fisher Scientific for their collaboration and support in the BAT; Nurse Aida and Nurse Alice for their work in blood collection. We are especially grateful to the patient.

#### Funding

The authors declare that no funding was received for the present study.

#### Conflicts of Interest

The authors declare that they have no conflicts of interest.

#### Previous Presentations

The present clinical case was presented as a poster at the National Congress of the Portuguese Society of Allergy and Clinical Immunology held in October/2017.

## References

- Morales DR, Lipworth BJ, Guthrie B, Jackson C, Donnan PT, Santiago VH. Safety risks for patients with aspirin-exacerbated respiratory disease after acute exposure to selective nonsteroidal anti-inflammatory drugs and COX-2 inhibitors: Meta-analysis of controlled clinical trials. *J Allergy Clin Immunol*. 2014;134:40-5.
- Kowalski ML, Asero R, Bavbek S, Blanca M, Blanca-Lopez N, Bochenek G, et al. Classification and practical approach to the diagnosis and management of hypersensitivity to nonsteroidal anti-inflammatory drugs. *Allergy*. 2013;68:1219-32.
- Asero R, Quarantino D. Cutaneous hypersensitivity to multiple NSAIDs: never take tolerance to selective COX-2 inhibitors (COXIBs) for granted! *Eur Ann Allergy Clin Immunol*. 2013;45:3-6.
- Layton D, Marshall V, Boshier A, Friedmann P, Shakir SA. Serious skin reactions and selective COX-2 inhibitors: a case series from prescription-event monitoring in England. *Drug Saf*. 2006;29:687-96.
- Ponce V, Muñoz-Bellido F, Moreno E, Laffond E, González A, Dávila I. Fixed drug eruption caused by etoricoxib with tolerance to celecoxib and parecoxib. *Contact Dermatitis*. 2012;66:107-8.
- Moutran R, Maatouk I, Hérou J. Etoricoxib-induced toxic epidermal necrolysis. *Int J Dermatol*. 2014;53:e275-7.
- Venturini Díaz M, San Juan de la Parra S, Segura Arazuri N. Selective immediate hypersensitivity to etoricoxib. *J Investig Allergol Clin Immunol*. 2008;18:485-7.
- Phillips-Angles E, Gonzalez-Muñoz M, Dominguez-Ortega J, Cabañas R, Quirce S. Usefulness of basophil activation test in diagnosis of hypersensitivity to etoricoxib. *J Allergy Clin Immunol Pract*. 2016;4:350-1.
- Koschel D, Cardoso C, Leucht V, Hoffken G. Asthmatic reaction induced by Etoricoxib in a patient with aspirin-sensitive asthma. *Allergy*. 2008;63(8):1093-4.
- Brockow K, Garvey LH, Aberer W, Atanaskovic-Markovic M, Barbaud A, Bilo MB, et al. Skin test concentrations for systemically administered drugs -- an ENDA/EAACI Drug Allergy Interest Group position paper. *Allergy*. 2013;68:702-12.

■ Manuscript received August 15, 2017; accepted for publication December 12, 2017.

**Mariana Couto**

Allergy Unit, Hospital CUF Porto  
Estrada da Circunvalação 14341, 4100-180 Porto  
E-mail: marianafercouth@gmail.com