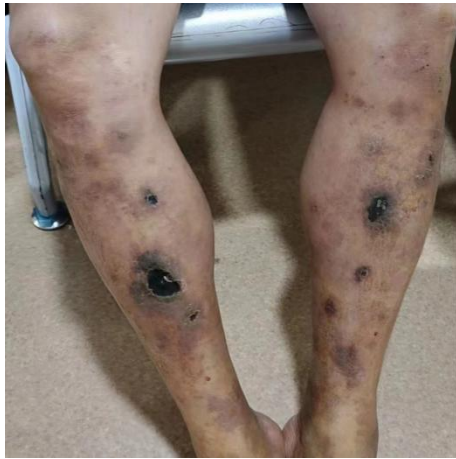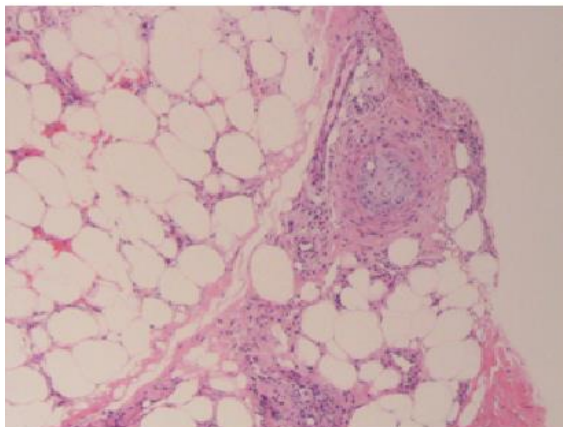


SUPPLEMENTARY MATERIAL

Supplementary Figure 1. Some irregular scabby lesions irregular scabby lesions



Supplementary Figure 2. Skin Biopsy showing eosinophilic infiltration and necrotizing eosinophilic vasculitis.