

## Two Nonimmediate Reactions to Oxaliplatin and Docetaxel Confirmed by Lymphocyte Transformation Test and Treated With Successful Rapid Desensitization Procedures

Berges-Gimeno MP<sup>1\*</sup>, Barra-Castro A<sup>1\*</sup>, Fernandez-Lozano C<sup>2</sup>, Solano-Solares E<sup>1</sup>, Martinez-Jañez N<sup>3</sup>, Pueyo-Lopez C<sup>4</sup>, Martínez-Botas J<sup>2\*\*</sup>

<sup>1</sup>Allergology Department, Hospital Universitario Ramón y Cajal, IRYCIS, Madrid, Spain

<sup>2</sup>Biochemistry-Research Department, Hospital Universitario Ramón y Cajal, IRYCIS, Madrid, Spain

<sup>3</sup>Oncology Department, Hospital Ramón y Cajal, IRYCIS, Madrid, Spain

<sup>4</sup>Pharmacy Department, Hospital Universitario Ramón y Cajal, IRYCIS, Madrid, Spain

\*Both authors contributed equally and should be considered first authors.

\*\*Both authors should be considered corresponding authors.

J Investig Allergol Clin Immunol 2025; Vol. 35(1): 70-72  
doi: 10.18176/jiaci.1030

**Key words:** Hypersensitivity. Oxaliplatin. Docetaxel. Desensitization. Lymphocyte transformation test.

**Palabras clave:** Hipersensibilidad. Oxaliplatino. Docetaxel. Desensibilización. Test de transformación linfocitaria.

Platinum compounds (PCs) and taxanes are among the chemotherapy agents that most frequently induce drug hypersensitivity reactions. Nonimmediate hypersensitivity drug reactions (NIHDRs) to PCs and taxanes are infrequent, with a limited number of cases published [1-3]. The most common NIHDR is maculopapular rash. Stevens-Johnson syndrome (SJS) has rarely been reported in association with taxanes and PCs [4].

Diagnosis of NIDHRs to chemotherapy drugs can be complex because the onset of these reactions is highly variable and several drugs could be involved [1,5]. Cancer patients are often exposed to multiple drugs in their chemotherapy cycles and may be taking several drugs for their underlying disease [1,6].

We report 2 NIDHRs to oxaliplatin and docetaxel confirmed by positive results in skin tests and the lymphocyte transformation test (LTT). Written consent was obtained from patients for both the study and the publication of the results.

Case 1 involved a 59-year-old man with gastric adenocarcinoma who developed widespread itchy exanthema 4 hours after the second exposure to oxaliplatin and racemic calcium folinate (leucovorin). The symptoms improved within a week with topical methylprednisolone and ebastine. Skin testing was performed with oxaliplatin (skin prick test [SPT], at concentrations of 0.5 mg/mL and 5 mg/mL and intradermal test [IDT] at concentrations of 0.5 mg/mL and 5 mg/mL) [6] and with leucovorin (SPT at concentrations of 1 mg/mL and

10 mg/mL and IDT at concentrations of 1 mg/mL) [6]. The immediate reading of the skin test results for oxaliplatin and leucovorin was negative, although the IDT with oxaliplatin (5 mg/mL) was positive after 48 hours. The results of a delayed reading of the skin test result with leucovorin and a drug provocation test (DPT) with leucovorin were negative.

The LTT was performed according to Giraldo-Tugores et al [7], namely, peripheral blood mononuclear cells (PBMCs) were isolated from whole blood using LymphoPrep gradient centrifugation. Cell suspensions (10<sup>6</sup> cells/mL) in AIM V Medium were added to each culture plate and stimulated with increasing concentrations of oxaliplatin (0.025 µg/mL, 0.25 µg/mL, 2.5 µg/mL, 25 µg/mL, 250 µg/mL, and 3 mg/mL). Cells treated with Dynabeads Human T-Activator CD3/CD28 (1 µL/well) (Gibco) were used as the positive control. The result was expressed as the stimulation index (SI), which was calculated as the ratio of the mean triplicate disintegrations per minute (dpm) of the drug-stimulated cultures compared with unstimulated cultures. SI<sub>3</sub> was considered a positive response in our evaluation [7]. LTT with oxaliplatin was positive at a concentration of 25 µg/mL and 2.5 µg/mL. LTT with oxaliplatin in 2 healthy controls and in 2 oxaliplatin-exposed patients revealed no proliferative responses (Figure).

The medical oncologist confirmed that oxaliplatin was a mandatory treatment. Based on risk stratification, a 3-bag, 10-step intravenous rapid drug desensitization (RDD) procedure was performed with oxaliplatin according to the Ramon y Cajal University Hospital (RCUH) protocol [1]. The patient underwent six RDD cycles with no breakthrough reactions.

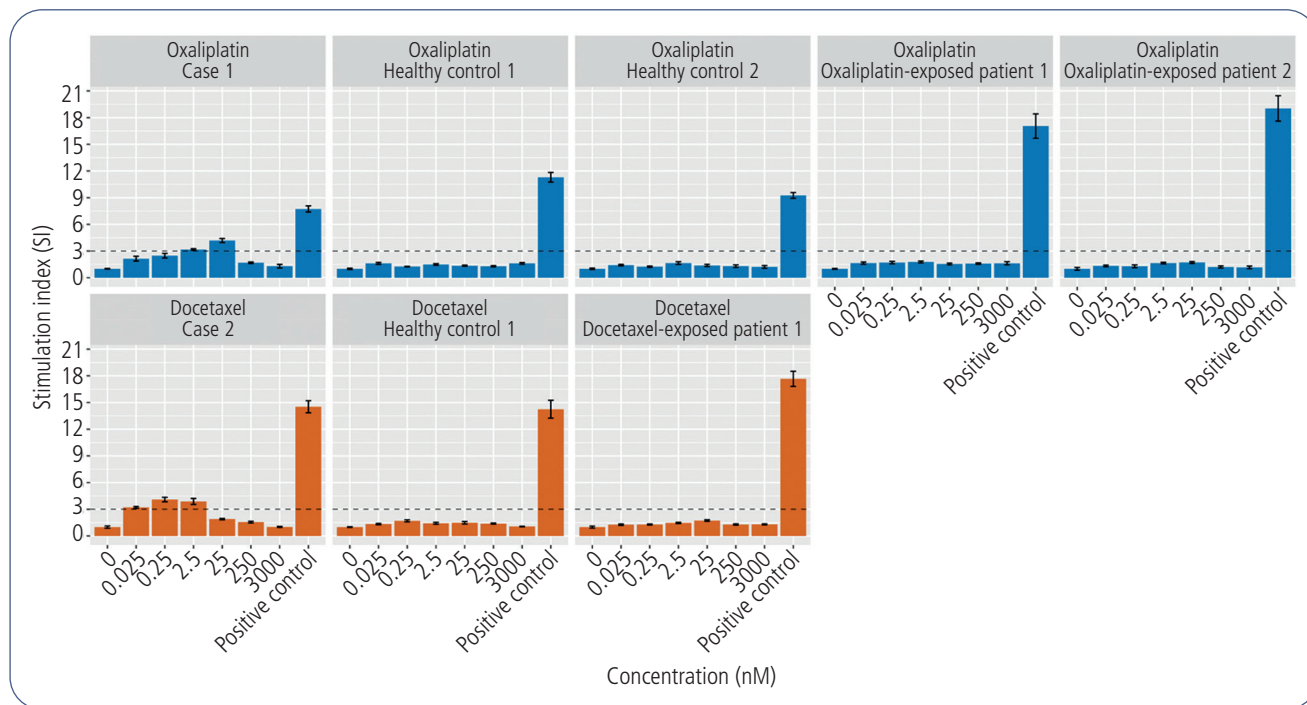
Case 2 involved a 50-year-old woman with breast cancer who developed facial erythema, gum pain, oral mucosal lesions, and odynophagia 24 hours after administration of docetaxel and cyclophosphamide. This was her first exposure to docetaxel and cyclophosphamide. The symptoms improved without medication, and the patient subsequently tolerated dexamethasone and ondansetron.

SPTs with docetaxel (1 mg/mL and 10 mg/mL) and cyclophosphamide (1 mg/mL and 10 mg/mL) [6] were negative. The immediate readings of IDT with cyclophosphamide and docetaxel (1 mg/mL) [6] were negative. A delayed reading of IDT with cyclophosphamide was negative, although a delayed, 7-day reading of IDT with docetaxel (1 mg/mL) was positive.

LTT was performed with increasing concentrations of docetaxel (28.8 ng/mL, 144 ng/mL, 720 ng/mL, 3.6 µg/mL, 18 µg/mL, and 90 µg/mL) [7]. LTT with docetaxel yielded a positive reading at concentrations of 720 ng/mL, 144 ng/mL, and 28.8 ng/mL. LTT was negative in a healthy control and in 1 docetaxel-exposed patient (Figure).

The medical oncologist confirmed that docetaxel and cyclophosphamide were mandatory treatments. The result of the DPT with cyclophosphamide was negative. A 3-bag intravenous, 10-step RCUH RDD protocol with docetaxel was used. Forty-eight hours after the first RDD cycle, the patient experienced facial erythema, which improved after treatment with topical hydrocortisone. Two weeks later, she underwent a second RDD with docetaxel. No breakthrough reactions were observed.

The diagnostic approach to NIDHRs should include a detailed clinical history documenting possible offending drugs



**Figure.** Lymphocyte transformation test results for cases 1 and 2. The SI was calculated as the ratio of [<sup>3</sup>H]-thymidine incorporated by drug-stimulated cultures and baseline [<sup>3</sup>H]-thymidine incorporation by unstimulated cells. As standard criteria, an SI $\geq$ 3 in at least 1 concentration (above the dotted line) was considered positive. Cells treated with Dynabeads Human T-Activator CD3/CD28 were used as a positive control. All results are shown as mean (SEM).

with precise dates in chronological order and a diagnostic allergy study for each drug involved. Current testing used for NIDHRs to antineoplastic agents includes delayed-reading IDTs and DPTs in nonsevere cases [2,3,5,6].

Positive delayed skin test readings have been reported in rare cases of NIDHRs to oxaliplatin [2] and docetaxel [5]. In case 1, IDT with oxaliplatin was positive after 48 hours and in case 2, IDT with docetaxel was positive 7 days later. Owing to the possibility of later positive IDT readings (after 48 hours), additional hyper-late readings can be performed, or patients should be instructed to report any skin reaction at the test site on subsequent days.

DPT is a helpful diagnostic technique in nonsevere NIDHRs that can prevent unnecessary desensitizations [8]. However, there are no guidelines for DPT in NIDHRs to chemotherapy, and practicalities such as training patients to monitor for delayed reactions at home must be considered.

The underlying mechanism of NIDHRs to antineoplastic agents is not completely understood [6]. Our results demonstrate the *in vitro* activation and expansion of the drug-specific memory T cells following incubation of the patient's PBMCs with oxaliplatin and docetaxel. Positive LTT results have only been reported with atezolizumab [7] and nivolumab [9]. It is important to be aware of the limitations of LTT, which has not been validated for antineoplastic drugs. Studies with larger numbers of patients and controls are needed [10].

Experience with RRD is limited. Nevertheless, the technique warrants careful consideration in patients who experience nonsevere NIDHRs induced by chemotherapeutic

drugs [5]. In the cases we report, the patients underwent RRD, which allowed them to continue their first-line cancer treatment.

We report a positive LTT result in a confirmed NIDHR to oxaliplatin and docetaxel. Although our findings add to an already large body of knowledge suggesting that LTTs may help to understand the underlying pathological mechanisms of NIDHRs and improve diagnosis, further studies are needed to determine the role of the LTT in these reactions.

#### Funding

This work was supported by a grant from Instituto Carlos III, ISCIII PI18/00962 cofunded by ERDF, "A way to make Europe" and a grant from Instituto Fundación Merck Salud, Spain.

#### Conflicts of Interest

The authors declare that they have no conflicts of interest.

#### References

- Vega A, Jimenez-Rodriguez TW, Barranco R, Bartra J, Diéguez-MC, Doña I, et al. Hypersensitivity Reactions to Cancer Chemotherapy: Practical Recommendations of ARADyAL for Diagnosis and Desensitization. *J Investig Allergol Clin Immunol*. 2021 Oct 25;31(5):364-84.
- Madrigal-Burgaleta R, Bernal-Rubio L, Berges-Gimeno MP, Carpio-Escalona LV, Gehlhaar P, Alvarez-Cuesta E. A Large

Single-Hospital Experience Using Drug Provocation Testing and Rapid Drug Desensitization in Hypersensitivity to Antineoplastic and Biological Agents. *J Allergy Clin Immunol Pract.* 2019 Feb;7(2):618-32.


3. Masse MS, Caimmi D, Demoly P. A delayed reaction to oxaliplatin. *J Investig Allergol Clin Immunol.* 2012;22(5):372-3.
4. Levin AS, Bhattacharya G, Blumental K, Camargo CA, Banerji A. Platin chemotherapy hypersensitivity reactions: expanding the scope of practice and improving care. *J Allergy Clin Immunol Pract.* 2019;7:1691-5.
5. Picard M, Pur L, Caiado J, Giavina-Bianchi P, Regnier Galvao V, Berlin ST, et al. Risk stratification and skin testing to guide re-exposure in taxane-induced hypersensitivity reactions. *J Allergy Clin Immunol Pract.* 2016;137:1154-64.
6. Gokulanathan P, Chandramouli R, Nadeem N, Sree SY. A Diagnostic Quandary: Carboplatin-Paclitaxel-Induced Stevens-Johnson Syndrome in a Rare Case of Carcinosarcoma of the Esophagus and Review of the Literature. *Cureus.* 2023 Oct 22;15(10):e47457.
7. Giraldo-Tugores M, Fernández-Lozano C, Carrón-Herrero A, Gajate P, Martínez-Botas J, Pueyo-López C, et al. Successful rapid desensitization to atezolizumab in delayed hypersensitivity confirmed with lymphocyte transformation test. *J Allergy Clin Immunol Pract.* 2022 Jun;10(6):1649-51.
8. Vega A, Peña MI, Torrado I. Use of Rapid Drug Desensitization in Delayed Hypersensitivity Reactions to Chemotherapy and Monoclonal Antibodies. *Front Allergy.* 2022 Jan 14;2:786863.
9. Rodríguez-Otero N, Chamorro-Perez J, Fernandez-Lozano C, Elias-Saenz I, Berna-Rico E, De Nicolas-Ruanes B, et al. Nivolumab-induced Stevens-Johnson syndrome: Not only due to PD-1 inhibition. *J Allergy Clin Immunol Pract.* 2023;11(9):2936-8.
10. Mayorga C, Ebo DG, Lang DM, Pichler WJ, Sabato V, Park MA, et al. Controversies in drug allergy: In vitro testing. *J Allergy Clin Immunol.* 2019;143(1):56-65.

■ *Manuscript received February 22, 2024; accepted for publication July 29, 2024.*

**María Pilar Berges-Gimeno**

 <https://orcid.org/0000-0002-0313-4122>  
Hospital Universitario Ramón y Cajal  
Servicio de Alergología  
Carretera de Colmenar, km 9  
28034 Madrid, Spain  
E-mail: berges.pilar@gmail.com

**Javier Martínez-Botas**

 <https://orcid.org/0000-0002-5190-3619>  
Hospital Universitario Ramón y Cajal  
Servicio de Bioquímica-Investigación  
Carretera de Colmenar, km 9  
28034 Madrid, Spain  
E-mail: javier.botas@hrc.es